ANIMAL TISSUES

Department of Zoology
The Open University of Sri Lanka

Animal Tissues

Introduction

Cells group together in the body to form tissues. A **tissue** is an ensemble of cells, not necessarily identical, but from the same origin, that together carry out a specific function. These are called tissues because of their identical functioning. There are only four types of tissues that are dispersed throughout the body: **epithelial tissue**, **connective tissue, muscle tissue**, and **nerve tissue**. These four types of tissues are similar in that each consists of cells and extracellular materials. They differ, however, in that they have different types of cells, and different percentage composition of cells and extracellular materials.

In this session you will be learning about these four tissue types. The '*epithelial tissue'* covers organ surfaces such as the surface of the skin, the airways, the reproductive tract, the inner lining of the digestive tract etc. '*Connective tissue'* is a fibrous tissue, that protects and supports the body, holds the organs in place, binds organs together, stores energy reserves as fat, and provides immunity to body. The '*muscle tissue'* is formed from the active contractile muscle cells. Muscle tissue functions to produce force and cause motion, either locomotion or movement within internal organs. '*Nervous tissue'* is specialized to react to stimuli and to conduct impulses to various organs in the body which bring about a response to a stimulus.

In all the animals or phyla of kingdom Animalia, tissues are not evident. Animals belonging to the group Parazoa have only cells. All the animals belonging to the group Eumetazoa have tissues. In this group, a hierarchy of increasing complexity of body form is evident. Among the eumetazoans also, only vertebrates will have almost all the tissue types described here. In invertebrates, their presence is more evident in higher forms.

Epithelial tissue and connective tissue (except bone and blood), are discussed in detail in this session.

1.1 Epithelial tissue

Epithelial tissue or epithelium *covers every exposed body surface* to form a barrier to the outside world and controls absorption. Epithelium forms the surface of the skin, and the lining of the intestinal, respiratory, and urogenital tracts. Epithelium also lines internal cavities and passageways such as the chest, brain, eye, inner surfaces of blood vessels, and heart and inner ear. Therefore, epithelial tissue *derives from all three primary germ layers*; ectoderm, mesoderm and endoderm.

In general, epithelial tissue consists mostly of cells with little extracellular material. It is arranged in sheets and attached to a basement membrane. Blood vessels are absent but a nerve supply is present. This tissue has a high capacity for renewal.

Produced by the Open University of Sri Lanka
2014

Epithelial tissue is specialized to perform several functions.

- Epithelium provides *physical protection* from injury, drying out and possible microbial invasions.
- *It controls permeability* of a substance in its effort to enter or leave the body. Some epithelia are relatively impermeable; others are readily crossed.
- It *detects sensation* (sight, smell, taste, equilibrium, and hearing) and conveys the information to the nervous system. For example, touch receptors in the skin.
- It *contains glands* that secrete substances *outside the body* (exocrine glands) as well as *inside the body* (endocrine glands). Sweat glands or digestive glands are exocrine glands. Endocrine glands such as pancreas, thyroid, and pituitary gland secrete substances (hormones) into blood.

Epithelial tissue can be divided in to *two types*,

1. Covering and lining epithelium that forms the outer layer of the skin and some organs and
2. Glandular epithelium that constitute the secreting portion of glands.

1. Covering and lining epithelium

The arrangement of covering and lining epithelium reflects its location and function. The classification of the epithelium types are done according to the shape of the cell and the number of cell layers

Three shapes of the cell exist.

Squamous (flat) epithelium

Cuboidal epithelium

Columnar epithelium

Three types of layers exist.

Simple epithelium - only one cell thick

Stratified epithelium - with two or more cells thick

Pseudo-stratified columnar epithelium - with only one layer, but giving the appearance of many layers

Simple epithelium

Simple epithelium can be subdivided into three types according to the shape and function of its cells.

Squamous epithelium (Figure 1.1a)

Morphology: composed of thin, flat cells.

Locations: lining of the lung, kidney, blood vessels, heart and mouth

Functions: adapted for diffusion and filtration.

Simple cuboidal epithelium (Figure 1.1b)

Morphology: cells are roughly square or cuboidal in shape with a spherical nucleus in the centre.

Location: found in glands, lining of the kidney tubules and the germinal epithelium of ovaries and testes.

Functions: adapted for secretion and absorption.

Simple columnar epithelium (Figure 1.1c)

This epithelium exists in two forms:

(a) Non ciliated simple columnar epithelium

Morphology: Morphology: cells are elongated and column-shaped with elongated/oval nuclei located near the base of the cells. These cells contain **microvilli** and goblet cells

Location: lines most of the alimentary canal

Functions: Microvilli increase the surface area of the plasma membrane for absorption and goblet cells secrete mucus to serves as a lubricant to protect the epithelium.

(b) Ciliated simple columnar epithelium

Morphology: Columnar epithelial cells have cilia on their free surfaces

Location: Usually found in the air passages in the nose region and in fallopian tubes of females

Functions: Cilia beat in a certain direction causing the mucus to flow in that direction to propel foreign particles trapped in mucus, and to propel ova to uteri

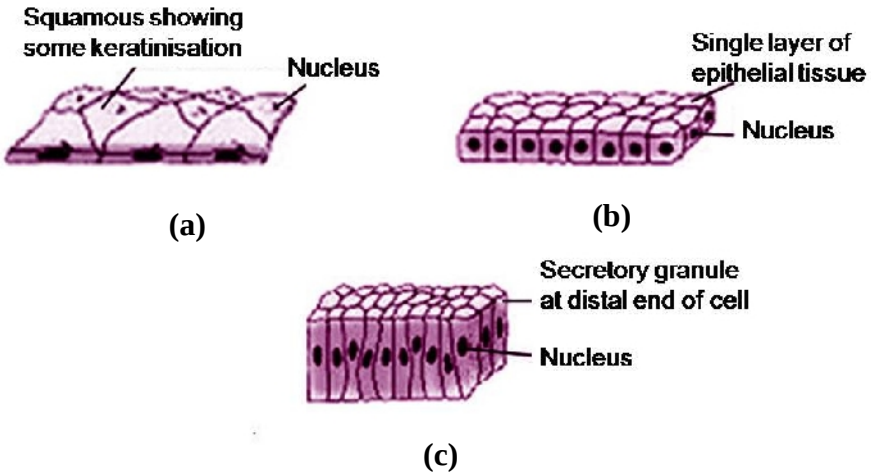

Figure 1.1: Simple epithelial tissues (a) Simple squamous epithelium (b) Simple cuboidal epithelium (c) Simple columnar epithelium

Stratified Epithelium

Stratified epithelium has at least two layers of cells. The name of the specific kind of stratified epithelium depends on the shape of the surface cells.

Stratified squamous epithelium (Figure. 1.2a)

Morphology: With many layers of cells and the topmost layer is made up of squamous cells looking like "piles of tiles", top cells are flat and scaly and it may or may not be keratinised (hardened with a tough, resistant protein called keratin)

Location: Skin is an example of dry, keratinised, stratified epithelium; lining of the mouth cavity, throat and esophagus have unkeratinisied, stratified epithelium.

Function: Protection

Stratified cuboidal epithelium (Figure. 1.2b)

Morphology: Several layers of cells in which the top layer is cube-shaped

Location: It lines larger excretory ducts such as salivary glands, mammary glands, sweat glands, and pancreas.

Function: Absorption and secretion

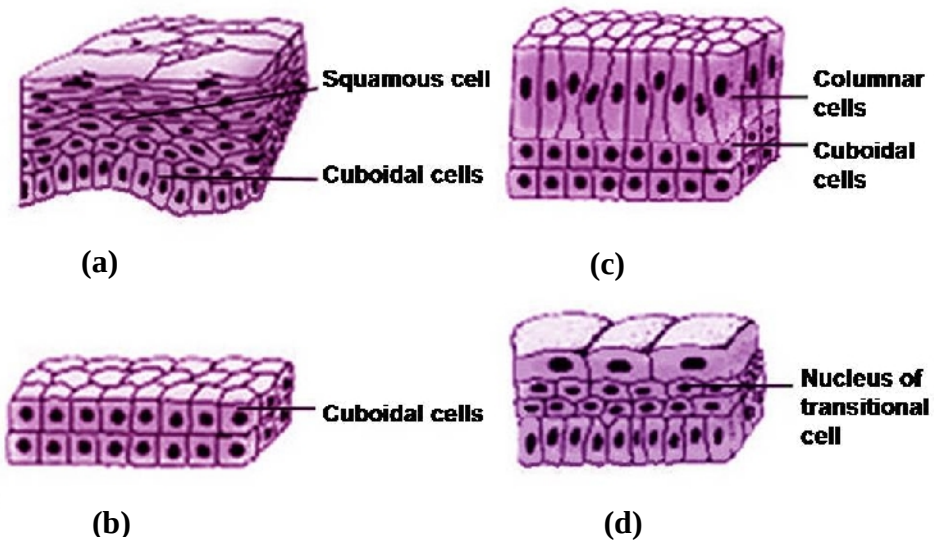

Figure 1.2: Stratified epithelial tissue types (a) Stratified squamous epithelium (b) Stratified cuboidal epithelium (c) Stratified columnar epithelium (d) Transitional epithelium

Stratified columnar epithelium (Figure. 1.2c)

Morphology: Many layers of cells and the topmost layer is made up of columnar cells

Location: Male urethra and vas deferens, parts of the pharynx

Function: Protection and secretion

Transitional epithelium (Figure. 1.2d)

Morphology: A stratified epithelium in which the shape of the surface cells changes (undergoes transitions) depending on the degree of stretch, when not stretched (empty bladder) the cells of the surface layers are large and rounded, when stretched (full bladder) the cells of the surface layers are pulled into a flattened shape

Location: Only in bladder, ureter and urethra

Function: Distension

Pseudo-stratified columnar epithelium (Figure. 1.3)

Morphology: Only one layer, but gives the appearance that it has many layers, looks as though some of the cells are not in contact with the basal lamina, and the nuclei are at different levels

Location: Lines larger excretory ducts, this epithelium with goblet cells, lines most of the major airways.

Function: Protection as well as secretion

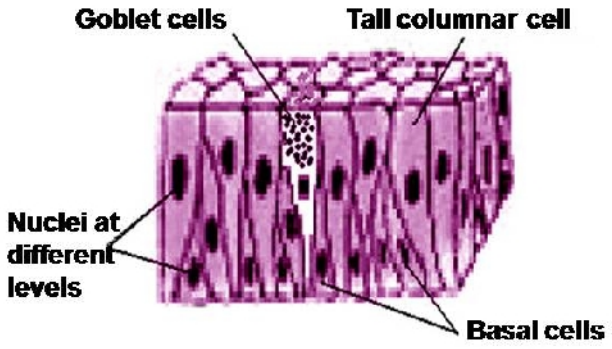

Figure 1.3: Pseudo-stratified columnar epithelium

2. Glandular epithelium

Glands are made up of single or a mass of epithelial cells. Columnar and cuboidal epithelial cells often become specialised as gland cells which are capable of synthesising and secreting certain substances such as enzymes, hormones, milk, mucus, sweat, wax and saliva. Unicellular glands are present as single, isolated glandular cells such as the goblet cells. Sometimes a portion of the epithelial tissue becomes invaginated and a multicellular gland is formed. Multicellular glands are composed of clusters of cells. Most glands in animals are multicellular glands.

Glands that secrete their product into ducts are called exocrine glands. Typical exocrine glands include sweat glands, salivary glands, mammary glands, stomach, liver, and pancreas. Those that secrete their product directly into the blood stream are called endocrine glands. The pancreas is both exocrine as well as an endocrine gland. This is because it secretes digestive juices into the small intestine via ducts and insulin into the blood stream.

There are 2 ways of classifying exocrine glands:

- according to their structure
- according to their function

Classification of exocrine glands according to their structure

Exocrine glands contain a glandular portion (lighter region) and a duct portion (darker region), the structures of which are used to classify the gland (Figure 1.4). They are called '*simple*' when the duct portion is unbranched and are called *'compound'* when the duct portion is branched. Tubular describes a gland whose secretary cells form a tube, while alveolar (or acinar) describes secretary cells that form a bulblike sac. Tubuloalveolar or tubuloacinar is used for a mix of the two types.

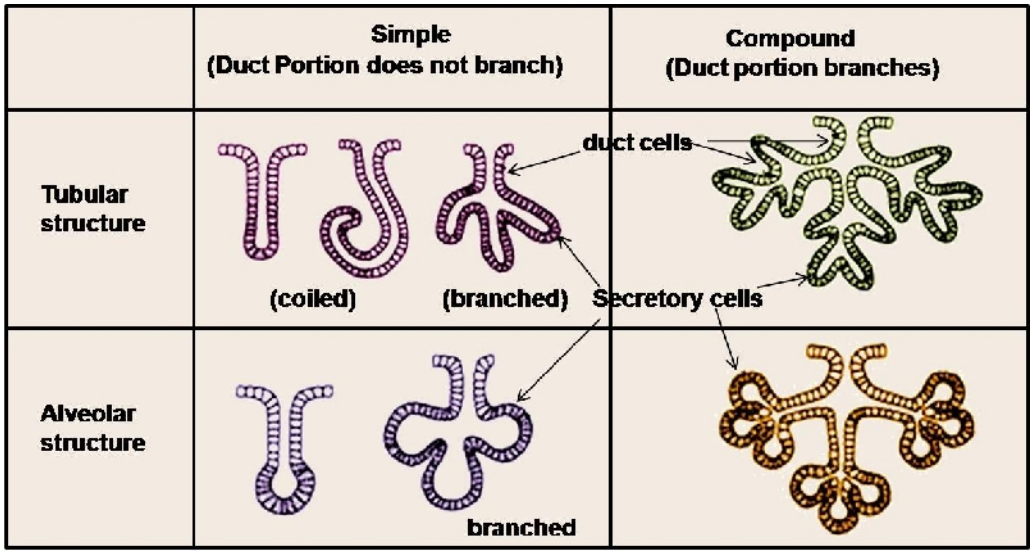

Figure 1.4: Classification of exocrine glands according to their structure

Examples for different structural types of glands

Simple tubular - Lieberkuhn's glands in intestine

Simple coiled tubular – Sweat glands of skin

Simple branched tubular – Pyloric glands of stomach

Compound tubular - Brunner's glands of duodenum

Simple alveolar – (rare)

Simple branched alveolar – Sebaceous gland of skin

Compound alveolar – (rare)

Compound tubuloalveolar – Mammary gland in the breast, Salivary glands

Classification of exocrine glands according to their function

The functional classification of exocrine gland is based on how secretions are released to the exterior.

a. Merocrine (or eccrine) glands (Figure. 1.5a)

These glands are the most common type of exocrine glands. Secretory granules (packaged in the Golgi bodies) migrate to the apical surface of the cell and their membranes fuse with the cell membrane of the apical region and release the secretion to the external environment by exocytosis. Examples of merocrine glands are the salivary glands and exocrine glands in pancreas.

b. Apocrine glands (Figure. 1.5b)

In apocrine glands, the apical portion of the cell containing secretion are budded off and released to the lumen or external environment. Examples of such apocrine glands are the apocrine sweat glands of the armpits.

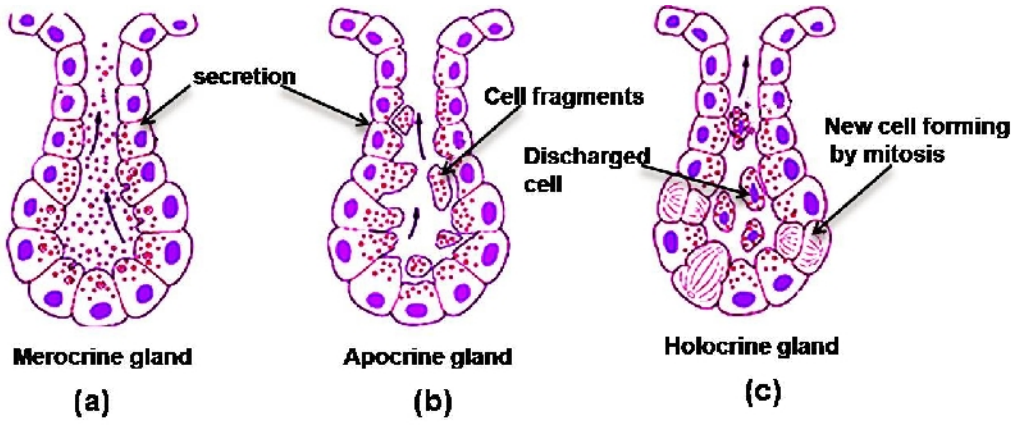

Figure 1.5: Classification of glands according to their function

c. Holocrine glands (Figure. 1.5c)

Holocrine glands accumulate secretory products in their cytosol and the cell dies. Dead cells are discharged and it is replaced by a new cell. The best example for this gland type is sebaceous glands associated with hair of thin skin.

Activity 1

What are the main functions of epithelial tissue?

Fill in the blanks given in the following table with the type of tissue to match the location and function given.

Location	Function	Type of Tissue
Male urethra and vas deferens, parts of the pharynx	Protection, secretion	…….
Lines the uterus and most organs of the digestive tract	Absorption	…….
Lines the respiratory passageways	Removing dust and particles from airways, has cilia	……..
Skin(keratinized) and the throat, vagina, mouth (soft)	Protects underlying cells	……
Lungs, walls of capillaries and vessels	Diffusion and Filtration	……..
Urinary tract	Specialized to become distended	…….
Glands, kidney tubules, ovaries	Secretion and Absorption	…….
Lines ducts of the mammary glands, sweat glands, pancreas	Protection	…….

2.2 Connective tissue

The most abundant and most widely distributed tissue in the body is connective tissue. It mainly binds structures together, forms a framework and support for organs and the body as a whole, protects and insulates internal organs and compartmentalizes structures such as skeletal muscles and nerves. Blood, a fluid connective tissue, helps to transport substances and protects the body against disease, while adipose tissue store fat.

Connective tissue is made up of cells, ground substances and fibers. Ground substances together with fibers make matrix. Connective tissue is characterized by an abundance of intercellular

matrix with relatively few cells. Connective tissue cells are able to reproduce but not as rapidly as epithelial cells. Most connective tissues have a good blood supply and nerve supply but some do not have them, e.g. cartilage. The matrix of the connective tissue is usually secreted by the connective tissue cells.

to the fundamental cell types, various leukocytes migrate from the bone marrow to connective tissues and provide various body defence activities:

- *Macrophages* engulf foreign and dead cells.
- *Mast cells* secrete histamine, which stimulates immune responses.
- *Plasma cells* produce antibodies.

Matrix fibers are proteins that provide support for the connective tissue. There are three types:

- *Collagen fibers*, made of the protein collagen, are both tough and flexible.
- *Elastic fibers*, made of the protein elastin, are strong and stretchable.
- *Reticular fibers*, made of thin collagen fibers with a glycoprotein coating, branch frequently to form a netlike (reticulate) pattern.

Ground substance may be fluid, semifluid, gelatinous, fibrous or calcified. It is only in blood the matrix is not secreted by cells in it. The ground substance mainly contains two types of substances:

- *Cell adhesion proteins* in it hold the connective tissue together.
- *Proteoglycans* provide the firmness of the ground substance, e.g. Hyaluronic sulphate and chondroitin sulphate.

Classification of connective tissue is based on composition that is the relative proportion of various cellular and extracellular components. However, the separation is not clear cut as the diversity of the components vary much. It is convenient to classify connective tissue as follows;

- Loose connective tissue
- Dense connective tissue
- Cartilage
- Bone tissue
- Blood tissue

(I) Loose connective tissue

In loose connective tissue, the fibres are loosely woven and there are many cells.

Areolar connective tissue (Figure. 1.6a)

This is one of the most widely distributed connective tissue in the body.

Cells: Several kinds of cells such as fibroblasts, macrophages, adipocytes, mast cells, and plasma cells are present.

Fibres: All three types of fibres; collagen, elastic and reticular are present.

Matrix: It consists of loosely arranged fibers in gelatinous ground substance.

Location: This forms the subcutaneous layer that attaches the skin to the underline tissues and organs and as a delicate thin membrane in most internal organs.

Function: Provide strength, elasticity and support.

Reticular connective tissue (Figure. 1.6b)

Cells: Only reticular cells are present.

Fibres: Only fine interlacing reticular fibres are present.

Matrix: It consists of loosely arranged fibers in gelatinous ground substance

Location: Stroma of liver, spleen and lymph nodes; bone marrow that gives rise to blood cells, basement membrane, around blood vessels and muscles.

Functions: Forms stroma of organs and bind together the cells of smooth muscles.

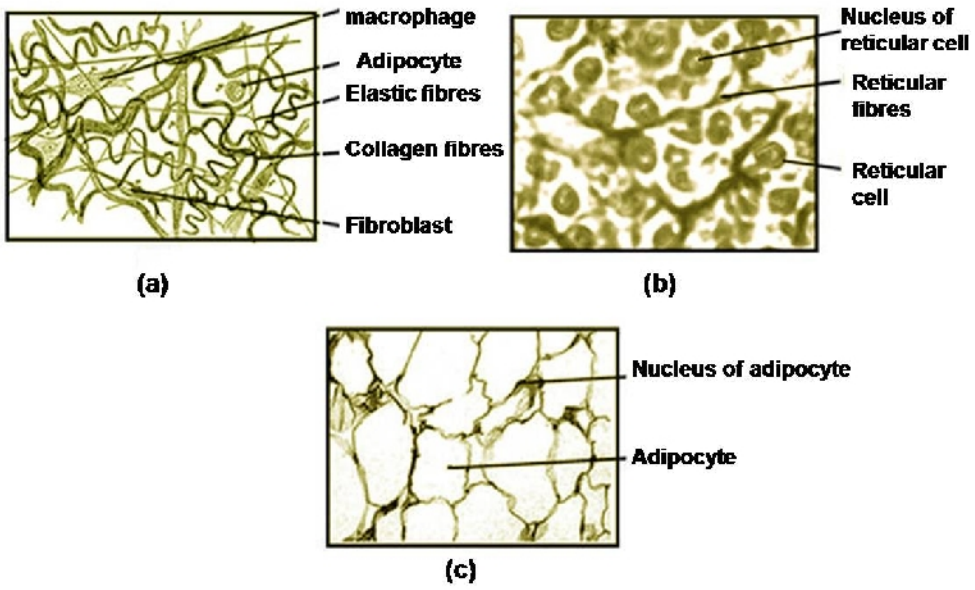

Figure 1.6: Loose connective tissue types (a) Areolar connective tissue (b) Reticular connective tissue (c) Adipose connective tissue

Adipose connective tissue (Figure. 1.6c)

Cells: Only adipocytes specialized to store fats are present. Adipocytes are derived from fibroblasts. Due to the accumulation of fat, the cytoplasm and the nucleus are pushed to the edge of the cell.

Fibres: Reticular and collagen fibres can be present.

Matrix: Due to close packing of cells a small amount of gelatinous ground substance and fibres are present

Location: Subcutaneous layer of skin, yellow marrow of bones and padding around joints.

Functions: Reduces heat loss through skin and serves as an energy reserve.

(II) Dense connective tissue

Dense connective tissue has few cells among a dense network of fibers with little ground substance. There are three types of dense connective tissue.

Dense regular connective tissue (Figure. 1.7a)

Cells: Fibroblasts cells appear in rows between the fibres.

Fibres: Bundles of collagen fibers have an orderly, parallel arrangement giving great strength.

Matrix: Ground substance appears in rows between fibres.

Location: Tendons and ligaments

Function: Provide strong attachments between structures.

Dense irregular connective tissue (Figure. 1.7b)

Cells: Few fibroblasts.

Fibres: Contains collagen fibres that are interwoven without regular orientation

Matrix: Irregularly arranged bundles of fibers with little ground substance.

Location: Found in parts of the body such as reticular (deeper) region of dermis, periostium of bone, perichondrium of cartilages, joint capsules, membrane capsules, around various organs and heart valves where tensions are exerted in various directions.

Function: Provide high strength.

Elastic connective tissue (Figure. 1.7c)

Cells: Fibroblasts present in spaces between fibres.

Fibres: Freely branching elastic fibres dominate. These fibres give the unstained tissue a yellowish colour.

Matrix: Abundant with freely branching elastic fibres with little ground substance.

Location: Lung tissue, walls of elastic arteries, trachea, bronchial tubes, vocal cords and ligaments between vertebrae.

Function: Allow stretching and regaining the original shape.



Figure 1.7: Dense connective tissue types (a) Dense regular connective tissue (b) Dense irregular connective tissue (c) Elastic connective tissue

(III) Cartilage

Cartilage is tough but flexible. It is capable of tolerating considerably more stress than the connective tissue. Its matrix consists of a dense network of collagen and elastic fibres firmly embedded in a chondrotine sulphate, a firm gel-like ground substance. It has cells that are distributed among fibers in ground substance. The fibres give the strength to the cartilage and chondrotine sulphate gives ability to assume the original shape. The cells of a mature cartilage called chondrocytes, are found singly or in groups within spaces called lacunae in the matrix.

The surface of a cartilage is surrounded by a membrane of dense irregular connective tissue called perichondrium. Unlike other connective tissue, cartilage has no blood vessels or nerves, except for those in the perichondrium.

There are three types of cartilages:

Hyaline cartilage (Figure. 1.8a)

Cells:	Numerous chondrocytes are present in lacunae.
Fibres:	Fine collagen fibres are present. They are not visible with normal staining techniques.
Matrix:	Consists of a bluish white and glossy ground substance with fine collagen fibres.
Location:	The most abundant type of cartilage. End of long bones, anterior end of ribs, nose, and part of larynx, trachea, bronchi and bronchi tubes.
Function:	Provide movements, flexibility and support at joints.

Fibrocartillage (Figure. 1.8b)

Cells:	Chondrocytes are scattered among bundles of collagen.
Fibres:	Clearly visible bundles of collagen fibres
Matrix:	Abundant with bundles of collagen fibres with little ground substance.
Location:	Pubic symphysis, intervertebral discs and menisci of knee.
Function:	Provide strength and rigidity.

Elastic Cartillage (Figure. 1.8c)

Cells: Chondrocytes are scattered among threadlike network of elastic fibres.

Fibres: A threadlike network of elastic fibres

Matrix: Abundant with elastic fibres with little ground substance.

Location: Epiglottis of larynx, external ear.

Function: Give support and elasticity to maintain shape.



Figure 1.8: Cartilage types (a) Hyaline cartilage (b) Fibro-cartilage (c) Elastic cartilage

(IV) Bone tissue

Depending on the structure, there are two types of bones; compact bones and spongy bones. Compact bone (Figure. 1.9a) is organized in units, called osteons (formerly known as the Haversian system). Each osteon consists of a central canal, which contains blood vessels and nerves, surrounded by concentric rings (lamellae) of hard matrix. The matrix consists of mineral salts, mostly calcium phosphate, that give bone its hardness and collagen fibers that give bone its strength. Between the lamellae are cavities (**lacunae**) that contain bone cells (**osteocytes**). **Canaliculi** radiate from the central canal allow nutrient and waste exchange with the osteocytes. They arise from the central canal at right angle to it and perforate the lamellae to connect with lacunae. These canaliculi consist of blood vessels that branch off from the central vessels in the central canals.

Spongy bone (Figure. 1.9b) has no osteons. Instead it consists of plates of bones called trabacullae which contain lamellae, osteocytes, lacunae and canaliculi. Spaces between trabaculae are filled with red bone marrow which produces blood cells.

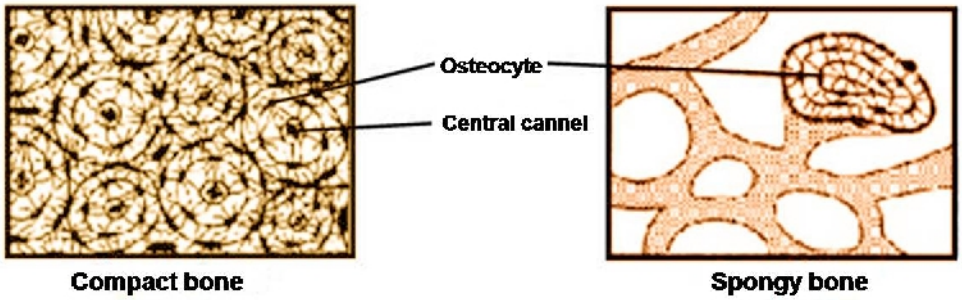

(a) (b)

Figure 1.9: Microscopic structure of (a) compact bone and (b) spongy bone.

(V) Blood tissue

Blood is composed of various blood cells and cell fragments (platelets) distributed in a fluid matrix called blood plasma (Figure. 1.10a). 55% of blood is blood plasma. Plasma is about 91.5% water and 8.5% solutes most of which are proteins (7%). Some of the proteins in the plasma are also found elsewhere in the body, but those confined to blood are called plasma proteins. Other solutes in plasma include waste products, nutrients, enzymes, hormones, gases and electrolytes. The cell types in blood are erythrocytes (red blood cells), leucocytes (white blood cells) and thrombocytes (platelets).

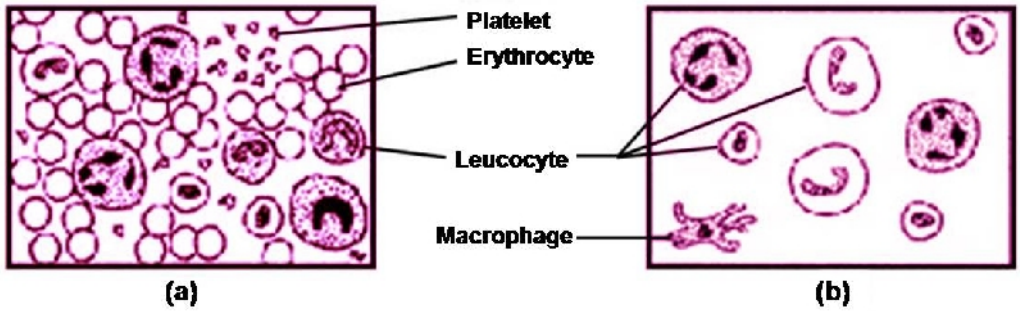

Figure 1.10: Microscopic structure of (a) blood and (b) lymph.

Most components of blood plasma freely move through the capillary walls to form **interstitial fluid**. Interstitial fluid and **lymph** are basically the same. When the interstitial fluid passes from interstitial spaces into lymphatic vessels, it is called lymph. Since most plasma proteins are too large to leave blood vessels, lymph contains only a small amount of protein. Lymph tissue contains large number of lymphocytes, one type of leucocytes (Figure. 1.10b).

Activity 2

Select the correct answer

1. The matrix of connective tissue is composed of

(a) Cells and ground substance.

(b) Cells and fibres.

(c) Fibres and ground substance.

(d) Cells, fibres and ground substance.

2. _____ tissue is found at the tip of the nose and outer ear.

(a) Loose connective

(b) Adipose

(c) Cartilage

(d) Bone

Produced by the Open University of Sri Lanka
2014

3. Which tissue type accomplishes the storage of fat?

(a) Adipose tissue
(b) Stratified epithelium
(c) Hyaline cartilage
(d) Dense fibrous tissue

4. What are the major functions of the connective tissue?

(i) It forms a framework and support for organs and the body.
(ii) It provides physical protection from injury and drying out.
(iii) It binds structures together.
(iv) It protects and insulates internal organs.

Correct responses are:

(a) (i) and (iii)
(b) (i), (ii) and (iv)
(c) (i), (iii) and (iv)
(d) all of them.

5. Which connective tissue type does not have a nerve or blood supply?

(a) Bones
(b) Cartilage
(c) Areolar tissue
(d) Dense elastic tissue

2.3 Muscular tissue

Muscle cells are elongated and referred to as muscle fibers. Muscle cells have four main properties:

Excitability (ability to respond to stimuli),

Contractibility (ability to contract),

Extensibility (ability to be stretched without tearing) and

Elasticity (ability to return to its normal shape).

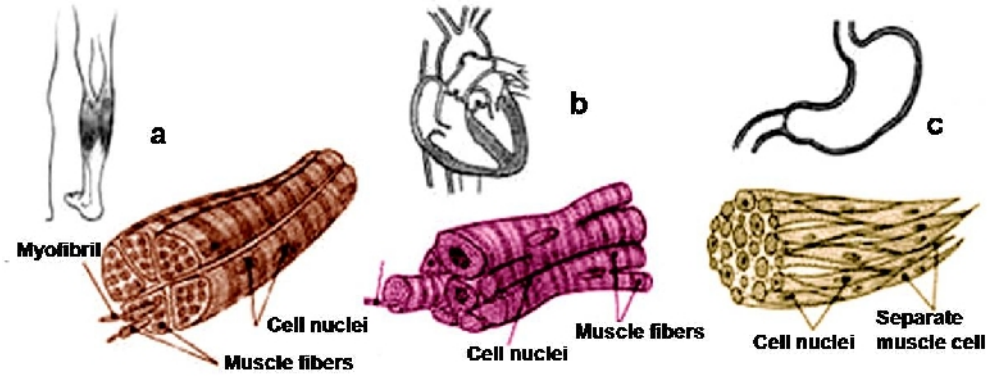

Figure 1.11: The three types of muscles in the body (a) skeletal muscle (b) cardiac muscle and (c) smooth muscle.

Muscles are commonly associated with movement. Muscle is a very specialized tissue that has both the ability to contract and the ability to conduct electrical impulses. Based on certain structural and functional characteristics, muscle tissue is classified into three types; skeletal, cardiac and smooth muscles (Figure. 1.11).

Skeletal muscles (Figure. 1.12)

These muscles are also known as **striated muscles** or voluntary muscles. As implied by the name, skeletal muscles are attached to bones by tendons and are responsible for skeletal movements. They are called striated muscles as their fibres (cells) contain alternating light and dark bands (striations) that are perpendicular to the long axes of the fibres. The movement of these muscles is under conscious or voluntary control.

The basic unit of a skeletal muscle is a muscle fiber. It is a single cylindrical long cell with many nuclei. The nuclei are arranged around the periphery of the cell just beneath the cell membrane. The characteristic striations seen are a result of the orderly arrangement of actin and myosin protein filaments within the muscle cell.

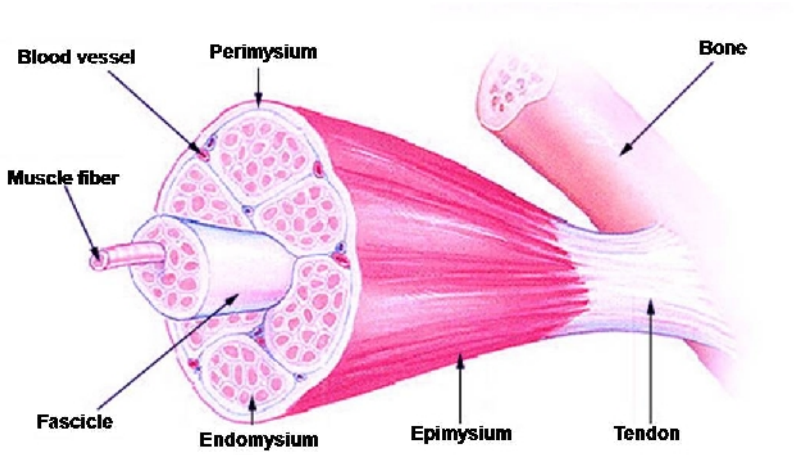

Figure 1.12: Structure of a skeletal muscle.

An individual skeletal muscle may be made up of hundreds, or even thousands, of muscle fibers (Figure. 1.12) bundled together and wrapped in a connective tissue sheath called the **epimysium.** Portions of the epimysium project inward to divide the muscle into compartments. Each compartment contains a bundle of muscle fibers. Each bundle of muscle fiber is called a fasciculus and is surrounded by a layer of connective tissue called the perimysium. Each muscle fibre is covered by a thin connective sheeth called, **endomysium**. Each skeletal muscle fibre acts independently of neighboring muscle fibers.

Cardiac muscle (Figure. 1.13)

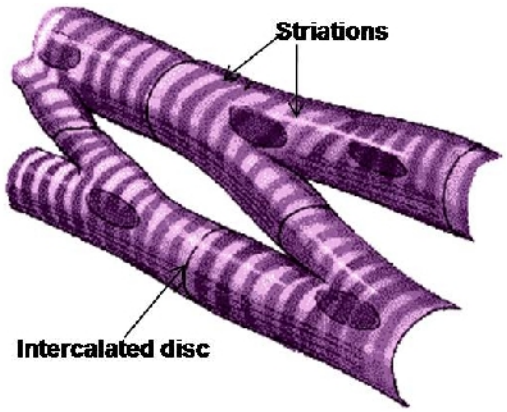

Figure 1.13: Structure of the heart muscle

This is a unique tissue found only in the walls of the heart. Cardiac (heart) muscle shows some of the characteristics of skeletal muscle and some of smooth muscle tissue. Its fibres, like those of skeletal muscle, have cross-striations. However, like smooth muscle tissue, it is involuntary. Usually, there is only one nucleus in the centre of each cardiac fiber, sometime there are two nuclei. The special feature in cardiac muscle fibers are that they are branched cylinders and they attach to each other by transverse thickenings of the **sarcolemma** called **intercalated discs**. These provide routes for quick conduction of impulses throughout the heart.

Smooth muscles (Figure. 1. 14)

Smooth muscle tissue is made up of thin-elongated muscle cells called smooth muscle fibres. These smooth muscle fibres are pointed at their ends and each has a single, large and oval nucleus. Every cell has many myofibrils, which lie parallel arrange to one another in the direction of the long axis of the cell. They are not arranged in an appropriate striated pattern, as in skeletal muscles. Smooth muscle fibres interlace each to form sheets or layers of muscle tissue rather than bundles. Smooth muscle is an involuntary tissue, i.e. its activity is not guided by the brain. Smooth muscle, spread and forms the muscle layers in the walls of hollow organs like digestive tract (oesophagus lower part, intestines and stomach), the bladder walls, the uterus, most ducts of glands and the blood vessel walls.

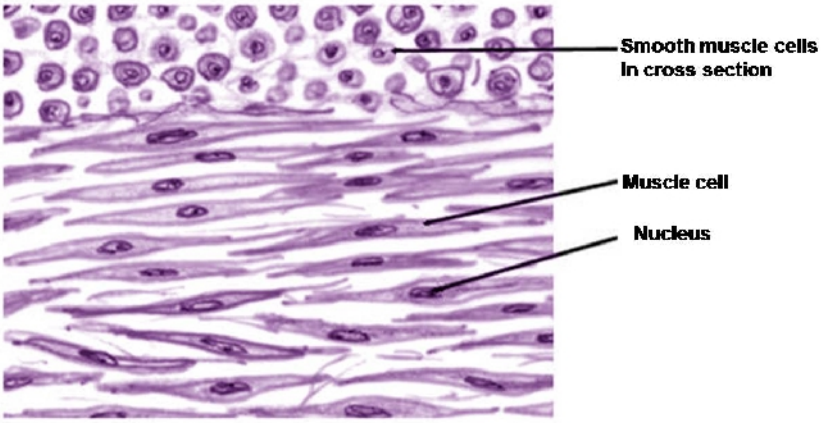

Figure 1.14: Structure of the smooth muscle

Activity 3

1. Explain how the properties of muscle cells are related to its function.
2. What is the typical biological function of muscle tissue?
3. Fill in the blanks in the following table to compare the structural and functional differences between the three muscle types

Character	Skeletal muscle	Cardiac muscle	Smooth muscle
Shape of the muscle fibre	Cylindrical, long	……..	Fusiform, short
No. of nuclei per cell	……	One or two	……..
Presence of striations	Yes	……	…….
Presence of intercalated discs	…….	……	No
Mode of control	……	Involuntary	……
Location	…….	……..	In the walls of hollow organs
	……	……	
Function	Movement of bones	……..	……
		……..	……

Produced by the Open University of Sri Lanka
2014

2.4 Nervous tissue

Nervous tissue is found in the brain, spinal cord, and nerves and consists of only two principal kinds of cells, neurons and neuroglia.

The cells in nervous tissue that generate and conduct impulses are called neurons or nerve cells. They are highly specialized cells that are sensitive to various stimuli. They convert these stimuli into nerve impulses and conduct them to other neurons, muscle fibers or glands. These cells have three principal parts: the **dendrites**, the cell body and one **axon** (Figure. 1.15a). The central cell body contains the neuron's nucleus, associated cytoplasm and other organelles. Dendrites are usually more numerous, shorter and more branched processes from the cell body. They typically carry signals toward the cell body. Axons are usually single long processes of the cell body that conduct nerve impulses away from the cell body.

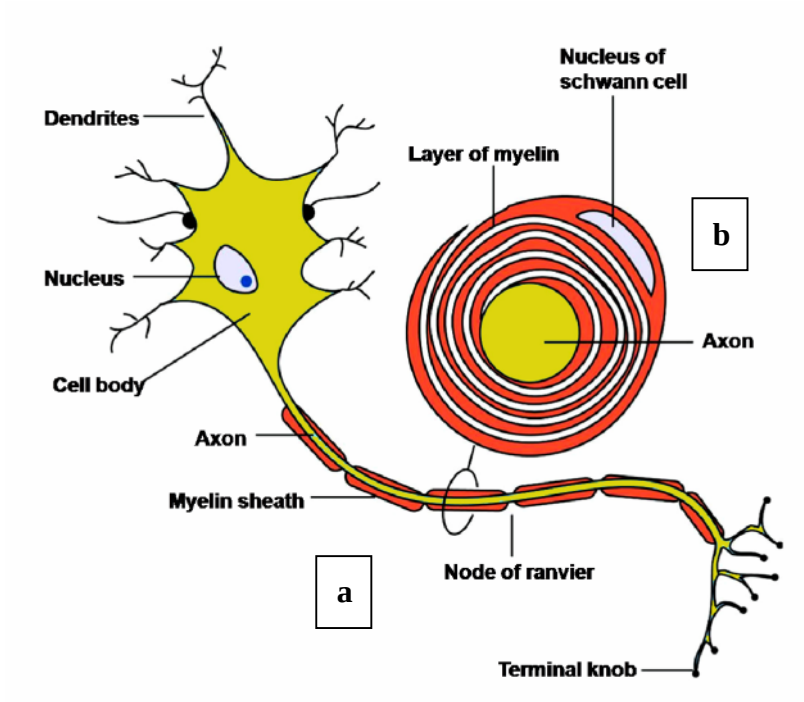

Figure 1.15: (a) Structure of a neuron (b) a cross section through the axon to show the myelin sheath produced by one type of neuroglial cells (schwann cell).

Nerve tissue also includes neuroglial cells that do not transmit impulses, but instead support the activities of the neurons. There are several types of neuroglial cells in the **central nervous system** as well as **peripheral nervous system** to perform several functions. They bind neurons together and insulate the neurons. Some are phagocytic and protect against bacterial invasion, while others provide nutrients by binding blood vessels to the neurons. Schwann cells, a type of neuroglial cell, produce the myelin sheath around axons of neurons in the peripheral nervous system only in mammals (Figure. 1.15b).

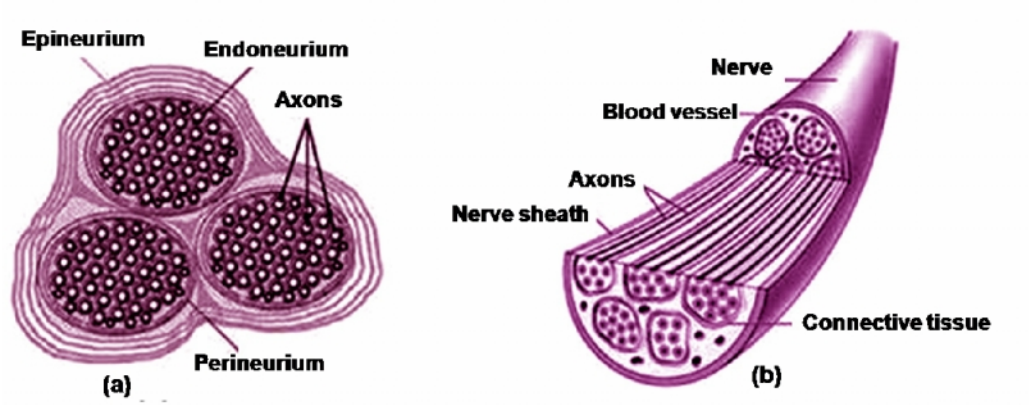

Figure. 1.16: Structure of a nerve in (a) a cross section, (b) 3- dimensional view

All nerves contain a large number of axons within it (Figure.1.16a & b). The individual axons of nerve fibres, whether myelinated or unmyelinated, are wrapped in a connective tissue sheath called endoneurium. Groups of fibres with their endoneurium are arranged in bundles called fascicles, and each bundle is wrapped in connective tissue called the perineurium. The outermost covering around the entire nerve is the epineurium. This arrangement is similar to the connective tissue arrangement in the skeletal muscle.

Activity 4

1. What is the typical biological function of the nervous tissues?
2. Give locations of the nervous tissue in the human body.
3. What are the functions of the neuroglial cells?

Summary

- There are 4 primary tissue types in the human body: epithelial tissue, connective tissue, muscle tissue and nerve tissue.
- The cells of epithelial tissue pack tightly together and form continuous sheets that serve as linings in different parts of the body and help the body to keep its organs separate, in place and protected.
- Epithelial tissue consists mostly of cells with little extracellular material and is attached to a basement membrane. It is without blood vessels, but with a nerve supply and high capacity for renewal.

- Connective tissue is characterized by an abundance of intercellular matrix with relatively few cells. The matrix has fibres (collagen, elastic and reticular) and ground substance. All elements of matrix are produced by the principal cell type in each variety of connective tissue.
- Connective tissue mainly binds structures together, forms a framework and support for organs and the body as a whole. It has a low capacity for renewal. Except cartilage, other types have a good blood supply and nerve supply.
- Smooth muscle fibres are fusiform with tapered ends, have a single centrally located nucleus, and do not exhibit striations. Cardiac muscle fibres are striated, have one or two centrally located nuclei, branch and are joined to one another by intercalated discs. Skeletal muscle fibres bear obvious striations, have many peripherally located nuclei, are of the same thickness throughout their length and do not branch.
- Nervous tissue is found in the brain, spinal cord, and nerves and consists of only two kinds of cells, neurons and neuroglia. Neurons have the ability to generate and conduct impulses in the body. Neuroglial cells do not transmit impulses, but instead support the activities of the neurons.

Learning Outcomes

By the end of this session you should be able to

- list the major functions of each of the four major animal tissue types (Activity 1, 2, 3 and 4)
- give the functions carried out by epithelial tissue types and state their general location/s (Activity 1).
- describe the basic features of connective tissue, and explain how the cells of this tissue type enable connective tissue to carry out its various tasks. (Activity 2)
- distinguish among skeletal, cardiac, and smooth muscle tissues in terms of location, structure, and function. (Activity 3)

Course Team

Course Team Chair

Dr. Nayana Nilakarawasam

Content Editors

Prof. Thusitha Jayasooriya
Dr. Nayana Nilakarawasam

Authors

Dr. Subadra Wijesekara
Ms. Nalana Edirisinghe
Dr. Nayana Nilakarawasam

Language Editor

Ms. Nirmalie Kannangara

Word Processing

Dr. Subadra Wijesekara
Ms. Nalana Edirisinghe
Dr. Nayana Nilakarawasam

Desktop Publishing

Mr. Tharindu Duminda Ramasinghe

Web Content Developer

Mr. Chameera Kendaragama

Graphic Artists

Mr. Tharindu Duminda Ramasinghe

First published: 2013

The Open University of Sri Lanka

Nawala, Nugegoda, Sri Lanka

ISBN – 978-955-23-1405-6

OER Transformation 2014